

## Glabellar Contraction Patterns: A Tool to Optimize Botulinum Toxin Treatment

ADA R. TRINDADE DE ALMEIDA, MD,\* ELISA R. M. DA COSTA MARQUES, MD,\* RAUL BANEGAS, MD,† AND BOGDANA V. KADUNC, MD, PhD\*

---

**BACKGROUND** Botulinum toxin is a well-established treatment for dynamic glabellar lines. A previous study evaluated the existence of glabellar contraction “patterns,” according to the predominance of eyebrow approximation, depression, or elevation movements, namely “U,” “V,” “convergent arrows,” “omega,” and “inverted omega.”

**OBJECTIVES** To confirm contraction patterns in the adult population for a better treatment approach and to verify whether changes occur after repeated treatment.

**METHODS** Pairs of photographs—at rest and under contraction—from two groups were retrospectively analyzed: 334 adult volunteers with a predominance of specific movements, being verified and 36 previously treated individuals when they returned for re-injections.

**RESULTS** The five glabellar contraction patterns were confirmed. Each individual’s initial pattern reappeared upon waning of the toxin effect.

**CONCLUSION** Interpersonal differences in facial animation are observed. Classifying glabellar wrinkles allows accurate treatment with botulinum toxin, injecting the most commonly recruited muscles with higher doses or into more sites. Muscles not so recruited are spared or injected with lower doses for more-effective and -natural results. Although botulinum toxin blockade causes recruitment of adjacent muscles, the initial muscle contraction pattern is resumed when the effect wanes.

*The authors have indicated no significant interest with commercial supporters in this article.*

---

The glabella is the first area to be noticed in the facial expression. Its contraction is associated with negative emotions, such as impatience, anger, and tiredness, which the individual often express in an unwanted manner.<sup>1</sup> The main muscles involved are corrugators and orbicularis oculi pars palpebralis (which approximate and depress the eyebrows), procerus, and depressors supercilii (depress) and frontalis (lift the eyebrows).<sup>2,3</sup>

The chemical denervation by botulinum toxin,<sup>4</sup> providing long-lasting, although reversible muscle relaxation,<sup>5</sup> has become the first-line cosmetic therapy for this area, which is one of the most

commonly studied in scientific publications on the subject.<sup>6,7</sup>

Most studies have considered that the glabellar lines act similarly in the majority of individuals, with only sex (heavier muscles and thicker skin in men),<sup>6,8–10</sup> age, ethnicity,<sup>11–14</sup> sun exposure, and physical activity-related differences.<sup>15</sup> For guidance, the literature provides injection models on the glabella, with three,<sup>15</sup> five,<sup>16–22</sup> and seven<sup>10,18,23,24</sup> injection sites that are distributed into the corrugators, procerus, and orbicularis oculi pars palpebralis muscles and indicated for all cases. This kind of approach is useful in comparative and

---

\*Dermatology Clinic, Hospital do Servidor Público Municipal de São Paulo, São Paulo, Brazil; †Centro Arenales, Buenos Aires, Argentina

multicenter studies, when standardization is a requirement. Unsatisfactory results, caused by inadequate pretreatment evaluation, suboptimal or excessive doses, or unrealistic expectations, are observed in daily practice, and in some cases the injected muscles are adequately immobilized, but the attempt to reproduce the suppressed movement causes the recruitment of adjacent muscles.<sup>13,25,26</sup>

Although all individuals have similar anatomy, how each one uses his or her facial musculature may differ greatly.<sup>27</sup> A pilot study had identified five glabellar contraction patterns<sup>28</sup> in 30 cases. But would such patterns be repeated in a larger sample? Could the change in the usual muscle usage by recruiting other adjacent muscles, while the treated ones remain relaxed, promote a functional “reeducation” and alter a person’s initial contraction pattern after repeated treatments? The intention of answering these questions motivated us to conduct the present study.

### Objectives

The objective of this work was to expand the case analyses to identify and classify the glabellar contraction patterns found in the adult population and to evaluate whether repeated treatment with botulinum toxin alters these patterns.

### Methods

This was a retrospective case analysis study that complied with the ethical rules of the 2000 Declaration of Helsinki. Two groups were evaluated.

#### *Group I*

Photographs were selected of 334 individuals from the authors’ private clinics and the Dermatology Clinic outpatient unit, Municipal Public Servant Hospital of São Paulo. Individuals with a previous history of ablative (dermabrasion, peelings, or lasers), surgical, or filling treatment in the region

and those having undergone treatment with botulinum toxin within 6 months before selection were excluded from the analysis. There were no restrictions regarding sex or phototype. The photographs were taken at rest and during forced contraction of the glabella (upon request) on the same day, keeping the camera, lighting, and distance constant.

#### *Group II*

Photograph pairs of 36 patients who received at least 4 botulinum toxin treatment sessions on the glabella were selected. There were no restrictions regarding sex or phototype. The photograph pairs (at rest and during maximum contraction) of the glabella were evaluated at least 4 months from the previous treatment session.

Two evaluators performed the analysis, which was standardized as follows. For each photograph, they observed the space between the eyebrows to detect the predominant movement—in an isolated manner or in association, that is, whether the movement was of approximation (eyebrows come together), depression (took a lower position than at rest), or elevation (a higher position than the initial one), to identify and classify the repetition of the possible contraction patterns.

### Results

#### *Group I*

Of the included cases, 288 were women (86.2%) and 46 were men (13.8%). Their age ranged from 27 to 70 (mean 43.4). The five patterns described in the previous study—two with simultaneous depression and approximation of the glabella but in different ranges, one only with approximation, one with simultaneous approximation and elevation, and one with predominance of depression—were the same as those observed in this new analysis. (Table 1 is a summary of the frequency of contraction patterns according to sex.)

**TABLE 1. Frequency of Contraction Patterns According to Sex**

Pattern	Male		Total
	N (%)	Female	
U	8 (17.4)	99 (34.4)	107 (32.0)
V	24 (52.2)	77 (26.7)	101 (30.2)
Converging arrows	9 (19.6)	55 (19.1)	64 (19.2)
Omega	4 (8.7)	30 (10.4)	34 (10.2)
Inverted omega	1 (2.2)	27 (9.4)	28 (8.4)
Total	46 (100)	288 (100)	334 (100)

### Glabellar Contraction Patterns

#### “U” Pattern

This pattern was the most frequently seen in the total group and in women, being found in 107 cases (32.0%), and the third most commonly seen in men. During contraction of the glabella, approximation and depression of the space between the eyebrows are observed, with variable intensity but little range and with the resulting movement taking the form of the letter “U.” At rest, the eyebrows form an arch. The muscles most often involved are the procerus and corrugators.<sup>2</sup> Patients with this pattern would be better treated using the classical five-injection-site model at the standard doses (Figure 1).

#### “V” Pattern

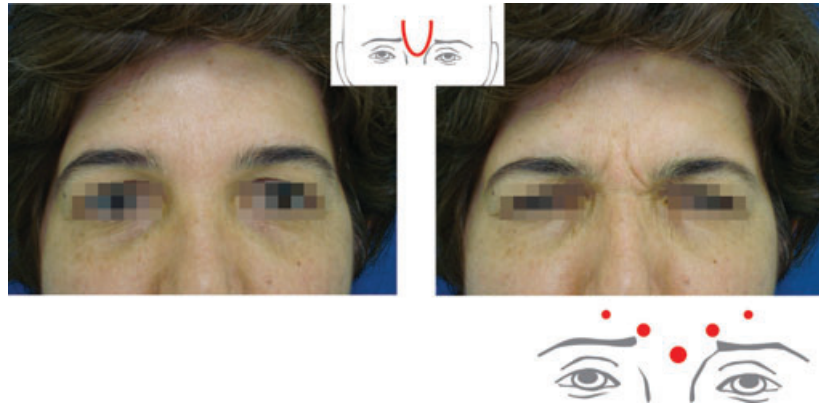
This pattern was observed in 101 individuals (30.24% of total cases). This was the second most frequently seen in women and the first in men. In this group, wide-range approximation and depression of the glabella occurred at a higher intensity than in the previous group. At rest, patients’ eyebrows are more horizontal or rectified and lower. In addition to higher corrugator and procerus muscle strength, there is important participation of the orbicularis medial portion. These patients require higher toxin doses into a greater number of injection sites, with the seven-site model being the best approach. The higher doses are concentrated at the procerus and corrugators (Figure 2).

#### “Converging Arrows” Pattern

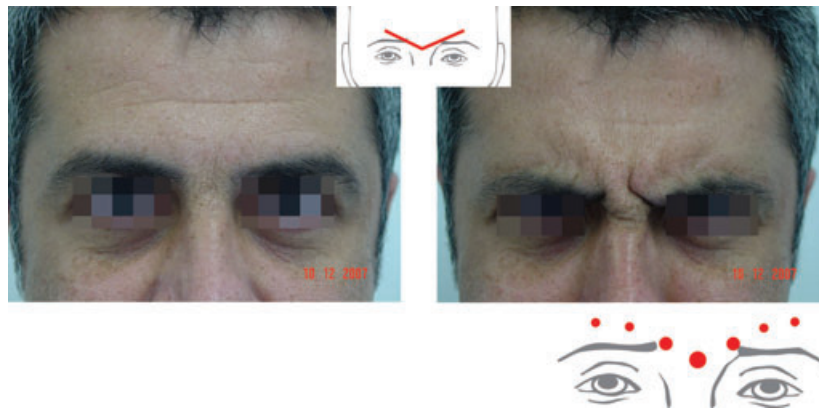This pattern was seen in 64 individuals (19.2% of cases)—the third most commonly observed pattern in the total group and in women and the second in men. This pattern may also be referred to as “brow opposers” (Alastair Carruthers, personal communication). Mainly, the approximation of the eyebrows occurs, with little or no depression or elevation. The resulting final movement is horizontal approximation. There seems to be a balance of

**TABLE 2. Muscles Interfering with the Glabellar Contraction Patterns**

Muscle	Origin	Insertion	Direction	Glabellar Function
Frontalis	Galea aponeurotica, below the coronal suture	Forehead skin; interdigitating with corrugator, procerus and orbicularis oculi pars palpebralis muscles	Vertical	Elevation
Corrugator	Nasal and frontal bony junction	Medial portion of the eyebrows	Horizontal and oblique (in some cases)	Approximation and depression
Procerus	Nasal bone	Subcutaneous and m. frontalis between the eyebrows	Vertical	Depression
Depressor supercillii	Superior-medial orbital arch	Dermis at the medial portion of the eyebrows	Vertical	Depression
Orbicularis oculi pars palpebralis	Canthus ligament	Medial orbital rim (frontal and maxillary bones)	Oblique (medial orbital pars) Vertical (internal orbital pars)	Approximation and depression
Nasalis	Maxilla	Aponeurosis of procerus and contralateral nasalis muscles	Transversal	Depression



**Figure 1.** Example of a “U” pattern of contraction that may be well addressed using the five-site injection scheme.



**Figure 2.** A patient classified as type “V” showing wide-range approximation and depression of the glabella needs a seven-site injection pattern.

forces between procerus and frontalis in this group. The muscles involved are corrugators and the medial portion of the orbicularis. The injection technique should be more horizontal, targeting the muscles involved. There is no need for injecting the procerus and frontalis muscles, or they may be injected at minimal doses (Figure 3).

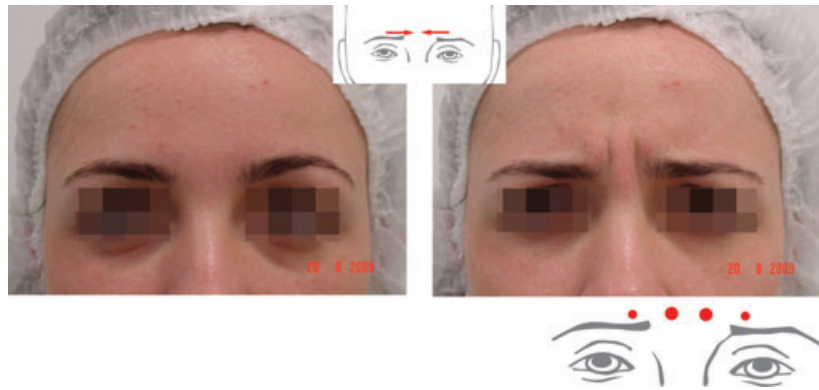#### “Omega” Pattern

This type was seen in 34 cases (10.2%), being the fourth most frequently seen in all groups. In this pattern, the predominant movements are approximation and elevation of the glabella, taking the form of the Greek letter omega. The dominant muscles are the corrugators, the medial portion of the orbicularis, and the frontalis, with little or no procerus contraction. The best approach for these cases

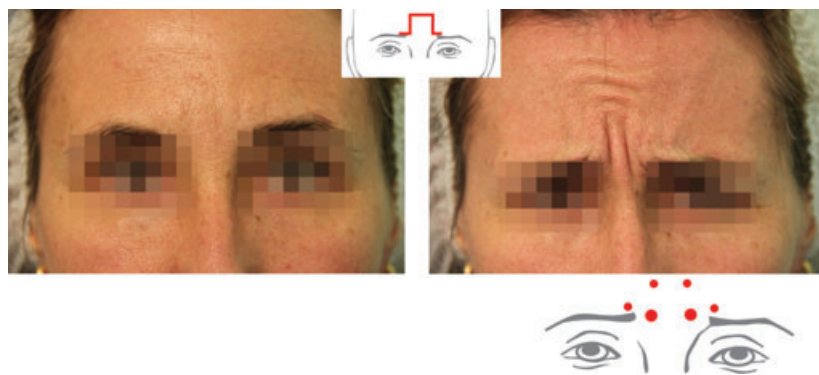would be to inject the toxin into the corrugators and orbicularis oculi pars palpebralis and into the medial portion of the frontalis muscle, with higher doses into the corrugators and orbicularis and lower doses into the frontalis sites. The procerus would be spared from treatment or would receive only a minimal dose (Figure 4).

#### “Inverted Omega” Pattern

This subgroup was identified in 28 cases, being the least frequently seen in our casuistic (8.4% of cases). The predominant movement is more depression than approximation (eyebrows barely join), resembling an inverted omega. The muscles involved are mainly the procerus, the depressor supercillii, the internal portion of the orbicularis oculi pars palpebralis, and perhaps the nasalis muscle, although this is not a



**Figure 3.** A case of brow opposer or converging arrows pattern with predominance of horizontal movement and the suggested injection sites.



**Figure 4.** The omega type of contraction showing simultaneous approximation and elevation of the glabella and its corresponding injection sites.

glabellar muscle.<sup>27</sup> In this group, there is less participation from the corrugators. It seems to be seen more often in patients with a flat nose apex. The most appropriate treatment would be higher doses injected into the procerus and depressors supercillii and additional sites at the internal portion of the orbicularis oculi pars palpebralis and nasalis muscles. A minimal dose may or may not be injected into the corrugators (Figure 5).

Individuals with asymmetrical eyebrows show different patterns on each side and may be classified and treated in two different manners.

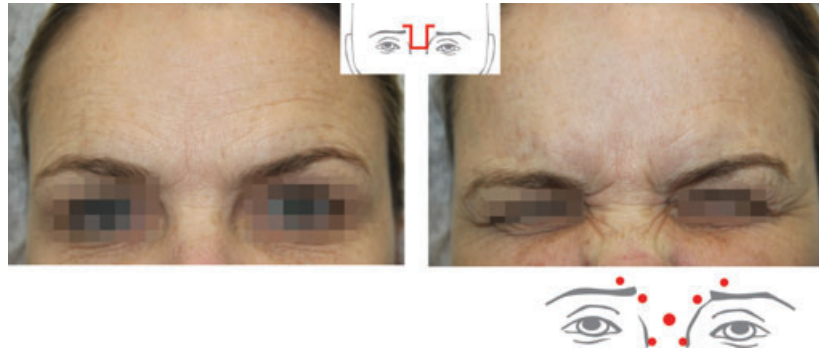### **Group II, with Multiple Injections**

Thirty-six patients (35 women and 1 man) underwent multiple botulinum toxin treatments. Their age ranged from 45 to 60 (mean 53). The distribution

was 20 cases with “U” and “V” patterns (10 (27.7%) each), six inverted omega (16.6%), and five omega and converging arrows patterns (13.8% each). The interval between injections ranged from 4 to 6 months, and the number of observed sessions ranged from five to 12, with a mean of 7.3 sessions per patient. All cases, regardless of initial identified pattern, returned to contract their muscles in a similar manner to the pretreatment period, after the toxin’s effect waned. Even when the recruitment of neighboring muscles occurred, the initial contraction pattern re-emerged with less strength, although being the same as initially seen (Figures 6A–E).

### **Discussion**

The balance between opposing muscles, mostly those lifting the facial skin (levators) and those



**Figure 5.** The inverted omega example showing predominance of depression and no approximation of the eyebrows and the suggested treatment sites.

depressing it (depressors) control facial expression. These muscles originate in the bone or at the superficial fascia, insert into the skin,<sup>29,30</sup> and are closely associated with each other, with synergic and antagonist activities.<sup>31</sup> During contraction, muscles follow force vectors that generally run from their insertion (mobile portion of the muscle) to their origin (fixed portion of the muscle),<sup>29,32</sup> determining hyperkinetic lines perpendicular to the contraction's direction and resulting in unaesthetic horizontal, vertical, and oblique wrinkles.<sup>3</sup> Table 1 summarizes the anatomy (origin, insertion, and direction) of the muscles influencing the contraction patterns of the glabella.

Variations in weight, strength, muscle activity,<sup>27</sup> and muscle insertion sites produce differences in the contraction patterns in different people. De Maio considers six variations in facial muscle contraction, classifying individuals as kinetic (regular contraction), hypokinetic (little expressiveness), and hyperkinetic (excessive mimic) and as tonic (regular muscle tone), hypertonic (always contracted, never relaxing), and hypotonic (excessive relaxation).<sup>31</sup>

More- or less-frequent muscle usage will determine the individual mimic patterns, and observation of these patterns allows a more-specific approach. Daily clinical practice teaches us that variations in dose, sites, and number of injection sites may alter final results and duration of treatment, influencing the patient's satisfaction and even the treating

physician's confidence in performing the procedure.<sup>31</sup>

The glabellar contraction patterns were not created. Rather, they have been noticed over the years and supported by colleagues in their personal communications, by the previous pilot study, and now, by the present study. Of the five described variants, the most commonly found were the "U" and "V" patterns, which could correspond to the two anatomical forms of the corrugators, as described by Macdonald in 1998: a short, pyramidal one, located at the medial edge of the supraorbital rim, and a long, narrow, rectified one extending from the supraorbital rim to the midpupillary line.<sup>30,33</sup>

Each type should be approached in a different manner when injecting botulinum toxin. Patients with a "V" pattern, if treated as a "U" type, will retain residual contraction, whereas treating an individual with a "U" pattern with "V" type sites and doses will cause a heavy look, and unnatural result. The brow opposer, or converging arrows pattern, is best treated with doses concentrated in the corrugators and the medial portion of the orbicularis oculi, which are the muscles responsible for approximating the eyebrows, with lower doses injected or not into the frontalis and procerus muscles. Regarding the omega pattern, where simultaneous contraction of the frontalis muscle during contraction of the glabella occurs, it is suggested that the central region of the frontalis



**Figure 6.** (A–E) Patients with each of the five contraction patterns (“U,” “V,” “converging arrows,” “omega” and “inverted omega”) after multiple botulinum toxin treatment sessions. Each photograph was taken when the patient returned for a new application.

muscle be injected, in addition to injection into the corrugators and the medial portion of the orbicularis oculi pars palpebralis. In cases of an inverted omega contraction pattern, the highest toxin doses should be injected into the procerus, depressors supercillii, and nasalis muscles, rather than the corrugators, because in these patients, the approximation between the eyebrows is less significant than the proximal depression. If corrugators are injected like in other patterns, the result will be a greater distance between the eyebrows and enlargement of the glabella. There is no consensus in the literature about the depressor supercillii being an independent muscle or part of the corrugator or orbicularis muscles,<sup>32</sup> but we consider it important to mention

it individually because it makes it easier to determine where to inject to better address the contraction patterns, especially the inverted omega.

It is important to make clear that, because the facial musculature is similar in all individuals, different contraction patterns might be observed in a single person at different moments. In some patients (probably in those whose corrugators are longer and in a horizontal position), the predominant movement seems to occur in two phases: initially, horizontal approximation (converging arrows) and then elevation (omega) or depression (“V”) of the glabella. This study aims not only to classify patients in a given fixed glabellar contraction group, but also

to highlight that the predominant pattern—the one that is most repeated—should not remain unidentified and incorrectly treated, because that is the one the patient uses most.

Other varying facial contraction regions have already been described. Rubin observed, according to the dominance of one or another muscle group,<sup>34</sup> three types of smiles: “Mona Lisa,” with the predominance of the action of the zygomatic major muscle and characterized by highly elevated mouth canthus; “canine,” with higher action of the levator labii superioris, in which cases the smile with strong elevation of the medial portion of the upper lip is manifested; and full denture smile, in which simultaneous contraction of the lip’s levators and depressors occurs.<sup>34</sup>

The use of Rubin’s classification allowed Kane to select which were the most appropriate cases to correct the deep nasogenial fold with botulinum toxin (the one with canine smile), avoiding unsatisfactory results in other patients.<sup>35</sup> In another article, based on the hyperkinetic segment of the orbicularis oculi muscle pars palpebralis,<sup>36</sup> this same author classified periorbital wrinkles as superior, inferior, central, and complete.

Tamura et al.<sup>37</sup> when studying nasal wrinkles, identified four types: nasal (the only muscle involved is the nasalis), naso-alar (nasalis and levator labii superioris alaeque nasi), naso-orbicularis (nasalis plus the nasal portion of the orbicularis oculi pars palpebralis), and naso-ciliary (nasalis and medial and nasal portions of the orbicularis oculi pars palpebralis).

Similarly, Braz and Sakuma<sup>38</sup> distinguished three variations in frontalis muscle contraction: total (the musculature would be continuous in the entire forehead extension, forming central wrinkles extending to beyond the midpupillary line), lateral (two lateral muscle bellies, without fibers in the center, forming wrinkles at the lateral portions of the forehead, beyond the midpupillary line), and

medial (wrinkles concentrated in the center of the forehead and possibly corresponding to a narrow frontalis muscle).

The reason for all those categorizations was to allow more-individualized treatment, with more-effective, natural results. More commonly recruited, hyperkinetic, or hypertonic muscles are treated with higher doses or a greater number of injection sites. Other less-used muscles receive lower doses or are spared. Other advantages would be to facilitate the training on botulinum toxin for beginners, as well as the discussion of unsatisfactory cases among specialists.

A change in the habitual use of the musculature is a phenomenon observed after treatment with neuro-modulators. In several facial regions, the recruitment of neighboring muscles to the paralyzed or relaxed ones by the medication occurs in an attempt to reproduce the blocked movement. Examples described after treatment of the glabella are nasalis contraction lines, forming the “Botox” sign, or “lateral recruitment” lines observed in the midpupillary region, just above the eyebrows, due to the action of the orbicularis oculi horizontal fibers, taking the function of the blocked corrugator.<sup>29,39</sup> In the same muscle, which is partially inactivated, recruitment of noninactivated muscle fibers may occur. Carruthers and Carruthers observed a change in eyebrow position after treatment of the frontalis with the toxin and concluded that partial inactivation of inferior-medial fibers promotes an increase in muscle tone in the remaining fibers with consequent eyebrow elevation.<sup>23</sup> The idea that these changes could promote muscle functional reeducation after years of repeated treatment with the toxin, with change in the initial glabellar contraction patterns, motivated us to reevaluate long-term treatment cases. Even when repeated recruitment of adjacent muscles to the blocked ones occurred, the initially predominant contraction patterns re-emerged with discontinuation of the medication. This ensures the temporary nature of the chemical denervation



caused by botulinum toxin and supports the safety of its long-term use.

## Conclusion

Achieving satisfactory, natural, and individualized results in the botulinum toxin treatment of the glabella requires the understanding that, although individuals' anatomy is similar, the way people use their musculature is variable. The classification of glabellar contraction patterns facilitates the identification of the predominant movement, allowing the dose to be concentrated in the involved muscles and sparing or avoiding those muscles less recruited. The initially predominant contraction patterns re-emerged with discontinuation of the medication. With this, treatment with botulinum toxin becomes more accurate and reproducible and remains safe over time.

## References

- Lewis MB, Bowler PJ. Botulinum toxin cosmetic therapy correlates with a more positive mood. *J Cosmet Dermatol* 2009;8(1):24–6.
- Sommer B, Sattler G, eds *Botulinum toxin in aesthetic medicine*. Blackwell Science: Berlin, 2001; pp. 30–1.
- Madeira CL, Marques EM. Noções de anatomia da face. In: Gadelha AR, Costa IMC, editors. *Cirurgia dermatológica em consultório*. Rio de Janeiro: Atheneu; 2003; pp. 77–94.
- Hankis CL, Strimling R, Rogers GS. Botulinum a toxin for glabellar wrinkles. Dose and response. *Dermatol Surg* 1998;24(11):1181–3.
- Carruthers A, Carruthers J, Lei X, Pogoda J. Onabotulinum-toxinA treatment of mild glabellar lines in repose. *Dermatol Surg* 2010;36:2168–71.
- Carruthers J, Fagien S, Matarasso SL, Alster T, et al. Consensus recommendations on the use of botulinum toxin type A in facial aesthetics. *Plast Reconstr Surg* 2004;114(Suppl 6):1S–22S.
- Carruthers J, Glogau R, Blitzer A. Facial aesthetics consensus group faculty advances in facial rejuvenation: botulinum toxin type A, hyaluronic acid dermal fillers, and combination therapies—consensus recommendations. *Plast Reconstr Surg* 2008;121(5):5S–30S.
- Draelos ZD. The shrinking word: skin considerations in a global community. *J Cosmet Dermatol* 2006;5(1):1–2.
- Flynn TC. Botox in men. *Dermatol Ther* 2007;20:407–13.
- Carruthers A, Carruthers J. Prospective, double-blind, randomized, parallel-group, dose-ranging study of botulinum toxin type A in men with glabellar rhytids. *Dermatol Surg* 2005;31(10):1297–303.
- Porter JP, Lee JI. Facial analysis: maintaining ethnic balance. *Facial Plast Surg Clin North Am* 2002;10(4):343–9.
- Ahn KY, Park MY, Park DH, Han DG. Botulinum toxin A for the treatment of facial hyperkinetic wrinkle lines in Koreans. *Plast Reconstr Surg* 2000;105(2):778–84.
- Matarasso S. Botulinum toxin: concepts and use in 2008. *Adv Dermatol* 2008;24:1–13.
- Monheit G, Carruthers A, Brandt F, Rand R. A randomized, double-blinded, placebo-controlled study of botulinum toxin type A for the treatment of glabellar lines: determination of the optimal dose. *Dermatol Surg* 2007;33(suppl 1):S51–9.
- Rexbye H, Petersen I, Johansens M, Klitkou L, et al. Influence of environmental factors in facial aging. *Age Ageing* 2006;35(2):110–5.
- Rzany B, Ascher B, Fratila A, Monheit G, et al. Efficacy and safety of 3-and 5-injection patterns (30 and 50 U of botulinum toxin A(Dysport) for the treatment of wrinkles in the glabella and the central forehead region. *Arch Dermatol* 2006;142(3):320–6.
- Carruthers A, Carruthers J. Clinical indications and injection technique for the cosmetic use of botulinum A exotoxin. *Dermatol Surg* 1998;24(11):1189–94.
- Carruthers J, Carruthers A. Botulinum toxin type A treatment of multiple upper facial sites: patient-reported outcomes. *Dermatol Surg* 2007;33(1 Spec No): S10–7.
- Fagien S, Cox SE, Finn JC, Werschler WP, et al. Patient-reported outcomes with botulinum toxin type A treatment of glabellar rhytids: a double-blind, randomized placebo-controlled study. *Dermatol Surg* 2007; 33(1 Spec No):S2–9.
- Levy JL, Pons F, Jouve E. Management of the ageing eyebrow and forehead: an objective dose–response study with botulinum toxin. *J Eur Acad Dermatol Venereol* 2006;20(6):711–6.
- Tiryaki T, Ciloglu S. Eyebrow asymmetry: definition and symmetrical correction using botulinum toxin A. *Aesthetic Surg J* 2007;27:513–7.
- Lehrer M, Benedetto A. Botulinum toxin— an update on its use in facial rejuvenation. *J Cosmet Dermatol* 2005;4:285–97.
- Carruthers A, Carruthers J. Eyebrow height after botulinum toxin type A to the glabella. *Dermatol Surg* 2007;33(1):S26–31.
- Bassichis B. Cosmetic use of botulinum toxin in the upper face. *Oper Tech Otolaryngol* 2007;18:248–53.
- Klein A. Complications, adverse reactions and insights with the use of botulinum toxins. *Dermatol Surg* 2003;29(5):549–56.
- Klein A. Contraindications and complications with the use of botulinum toxins. *Clin Dermatol* 2004;22:66–75.
- Fagien S, Raspaldo H. Facial rejuvenation with botulinum neurotoxin: an anatomical and experiential perspective. *J Cosmet and Laser Ther* 2007;9(Suppl 1):23–31.
- Trindade de Almeida AR, Marques ER, Kadunc BV. Glabellar wrinkles: a pilot study of contraction patterns. *Surg Cosmet Dermatol* 2010;2(1):23–8.
- Petrus GM, Lewis D, Maas CS. Anatomic considerations for treatment with botulinum toxin. *Facial Plast Surg Clin North Am* 2007;15(1):1–9.
- Macdonald MR, Spiegel JH, Raven R, Kabaker S, et al. An anatomical approach to glabellar rhytids. *Arch Otolaryngol Head Neck Surg* 1998;124:1315–20.

31. De Maio M. Mímica facial. In: De Maio M editor. Tratado de medicina estética. vol. 75. São Paulo: Roca; 2004. pp. 1321–5.
32. Knize DM. Muscles that act on glabellar skin: a closer look. *Plast Reconstr Surg* 2000;105(1):350–61.
33. Finn JC, Cox SE. Practical botulinum toxin anatomy. In: Carruthers A, Carruthers J. editors. Botulinum toxin. vol. 3. Philadelphia, PA: Elsevier Saunders; 2005. pp. 19–30.
34. Rubin LR. The anatomy of a smile: its importance in treatment of facial paralysis. *Plast Reconstr Surg* 1974;53(4):384–7.
35. Kane MC. The effect of botulinum toxin injections on the nasolabial fold. *Plast Reconstr Surg* 2003;112(5 Suppl):66S–72S.
36. Kane MC. Classification of crow's feet patterns among caucasian women: the key to individualizing treatment. *Plast Reconstr Surg* 2003;112(5 Suppl):33S–9S.
37. Tamura B, Odo M, Chang B, Cucé L., et al. Treatment of nasal wrinkles with botulinum toxin. *Dermatol Surg* 2005;31(3):271–5.
38. Braz AV, Sakuma TH. Patterns of contraction of the frontalis muscle. *Surg Cosm Dermatol* 2010;2(3):191–4.
39. Kaminer MS, Hruza GJ. Botulinum A exotoxin injections for photoaging and hyperhidrosis. In: Kaminer MS, Dover JS, Arndt KA, editors. Atlas of cosmetic surgery, (1st ed). Philadelphia, PA: Saunders; 2002. pp. 292–309.

---

Address correspondence and reprint requests to:  
Ada R. Trindade de Almeida, MD, Rua Fábria, 94  
apto.111A, Vila Romana, São Paulo, SP 05051–030,  
Brazil, or e-mail: artrindal@uol.com.br